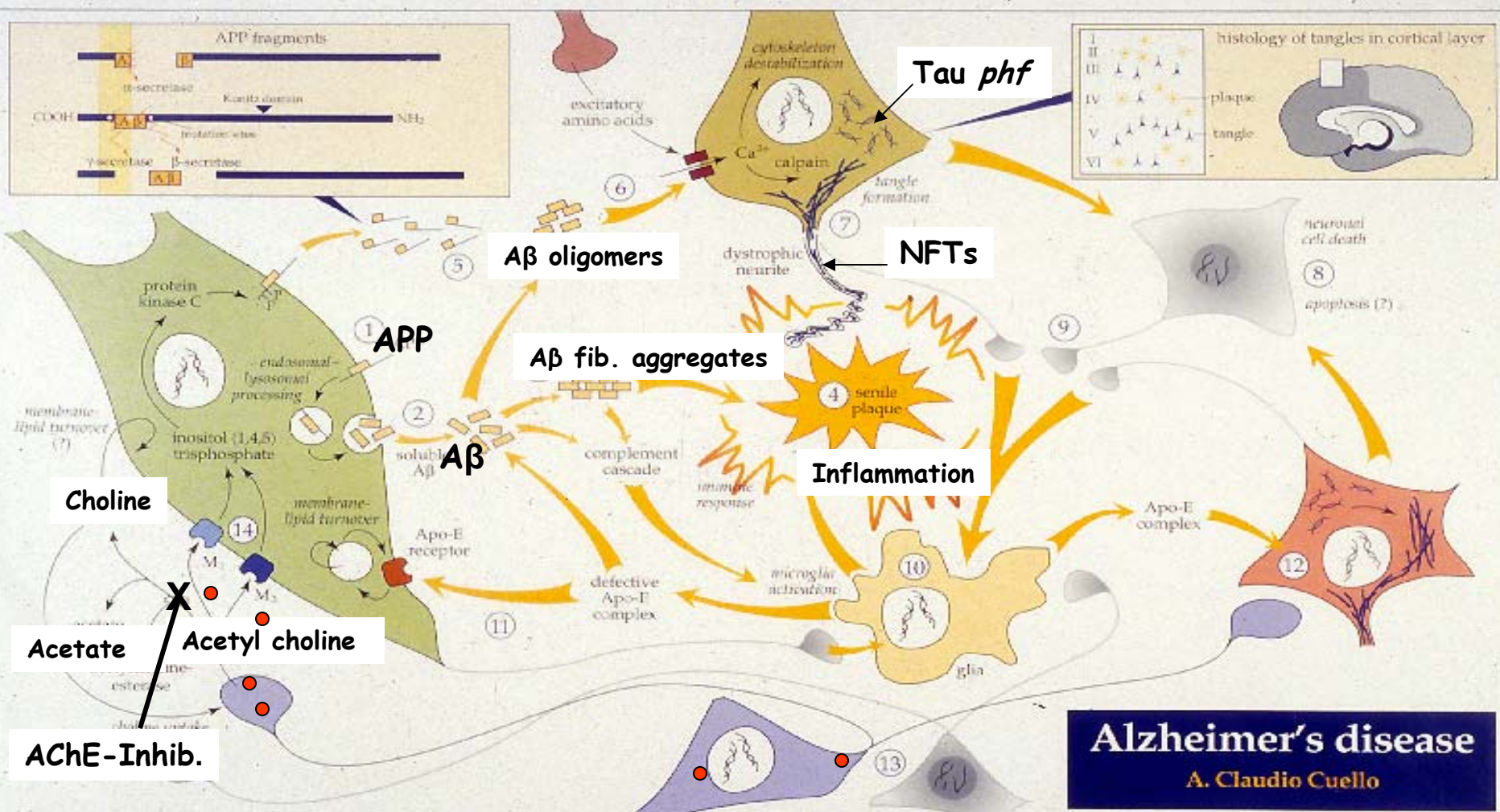


Main features of the Alzheimer's pathology



Forebrain Cholinergic Neurons